

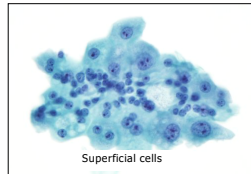
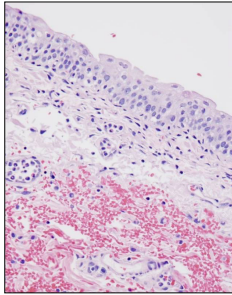
UR-ine Wonderland

Güliz A. Barkan, MD, FIAC
Professor of Pathology and Urology
Loyola University Medical Center, Maywood,
Illinois, USA

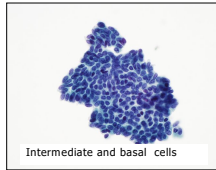
gbarkan@lumc.edu

Twitter handle :@barkanga

The Usual Suspects...

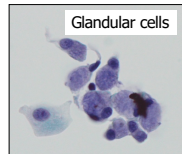
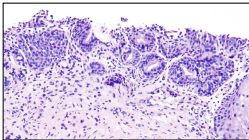


Superficial cells

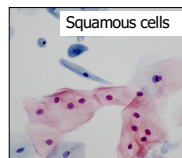
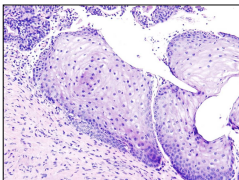


Intermediate and basal cells

More Usual Suspects...



Glandular cells



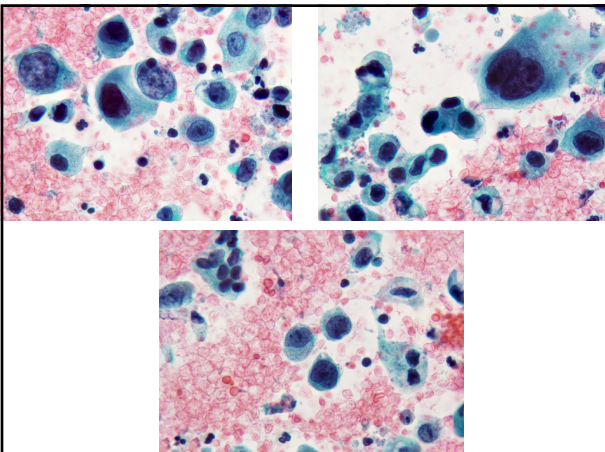
Squamous cells

Specimen Types

- Voided urine
- Instrumented urine
 - Catheterized urine
 - Bladder washing/barbotage
 - Upper tract washing/brushing
 - Urethra washing/brushing

Case 1

59-year-old man presenting with a recent episode of gross hematuria, lasting 2 days.
PMH: Kidney stone 5y ago, hypothyroidism, and hypertension.
Bladder barbotage specimen is presented.



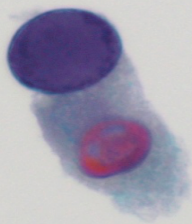
Case 1: What is your diagnosis?

- A. Negative for High Grade Urothelial Carcinoma (NHGUC)
- B. NHGUC Polyomavirus
- C. Atypical Urothelial cells (AUC)
- D. Suspicious for HGUC
- E. High grade Urothelial Carcinoma

Differential Diagnosis of “Large Cells” in Urine

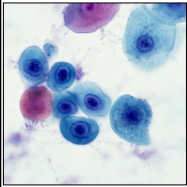
- Normal / reactive urothelial cells
- Polyomavirus effect
- Other viruses
- Seminal vesicle cells
- Treatment (chemotherapy) effect
- Urothelial carcinoma, high grade
- Squamous cell carcinoma (nonkeratinizing)
- Other neoplasms (large cell lymphoma, melanoma)

Polyomavirus Effect

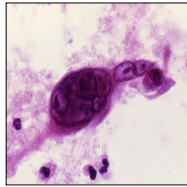


Other viruses

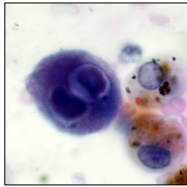
Courtesy of Dr. Bernard Naylor



Adenovirus

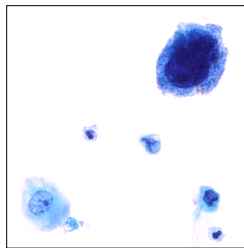
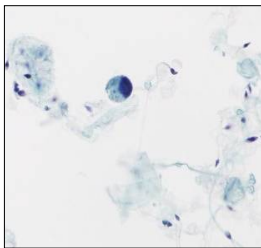


Herpes

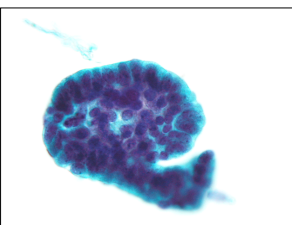
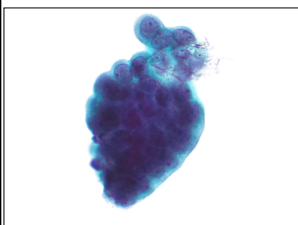


Cytomegalovirus

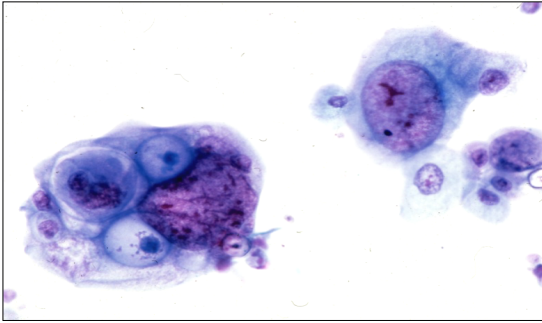
Seminal Vesicle cells



Urolithiasis

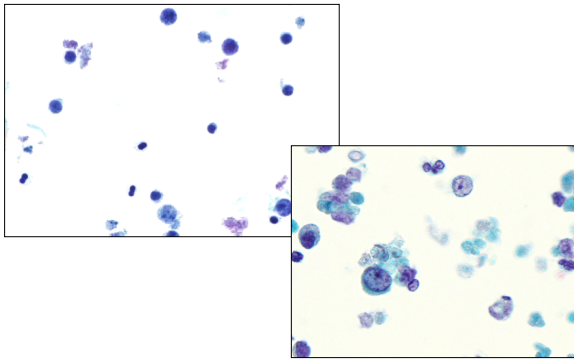


Chemotherapy effect



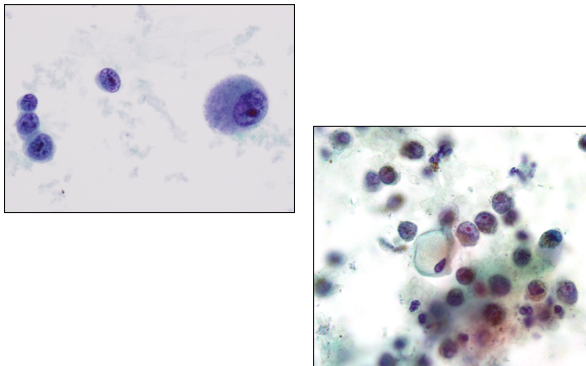
Courtesy of Dr. Bernard Naylor

Lymphoma

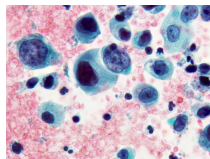


Anaplastic large cell lymphoma involving the urinary bladder: a case report and review of the literature.
Chen H, Li Y, Nand S, Quek ML, Kini AR, Barkan GA.
Diagn Cytopathol. 2015 Jan;43(1):60-5.

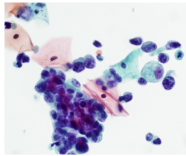
Melanoma



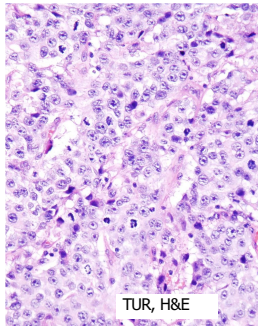
**Case 1 Diagnosis:
High Grade Urothelial Carcinoma**



cytospin



ThinPrep

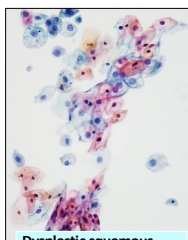


TUR, H&E

Features of High Grade UC

- Cellular
- Single cells, cells in groups
- Shape: irregular, plasmacytoid, may be pleomorphic
- **Nuclear enlargement with increased N:C ratio (>0.7)**
- **Coarse chromatin**
- **Hyperchromasia**
- **Irregular nuclear membrane**

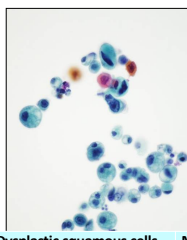
Problem: Squamous Cells



Dysplastic squamous cells and normal urothelial cells

Dysplastic cells from penile urethra

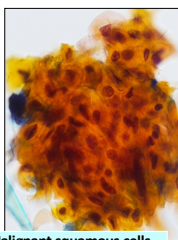
Dysplastic cells from genital tract



Dysplastic squamous cells and atypical/malignant urothelial cells

Urothelial carcinoma with squamous differentiation

Poorly differentiated squamous cell carcinoma

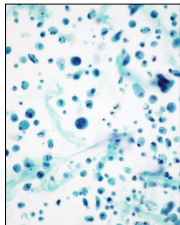


Malignant squamous cells and normal/reactive urothelial cells

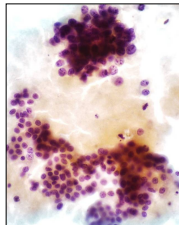
Squamous cell carcinoma

Urothelial carcinoma with squamous differentiation

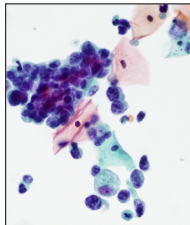
High Grade UC- Different Preparations



Surepath



Cytospin



ThinPrep®

Poll Question: What preparation type are urine specimens prepared with in your laboratory?

- A. Cytospin
- B. SurePath™
- C. ThinPrep
- D. Other
- E. I am not sure


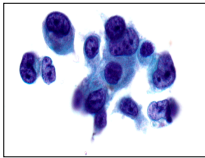
The Paris System of Reporting Urinary Tract Cytology: Categories

- I. Unsatisfactory/Nondiagnostic
- II. Negative for High Grade Urothelial Carcinoma
- III. Atypical Urothelial Cells
- IV. Suspicious for High Grade Urothelial Carcinoma
- V. High Grade Urothelial Carcinoma
- VI. Low Grade Urothelial Neoplasm
- VII. Other malignancies, both primary and secondary
- VIII. Ancillary Studies
- IX. Clinical management
- X. Preparatory techniques relative to Urinary Tract samples

What really matters in urine cytology?

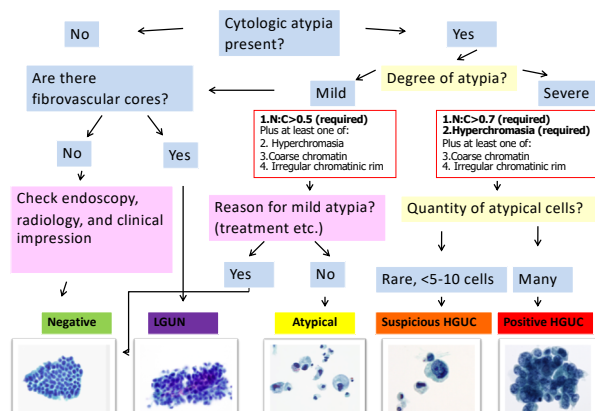
- Basis of the Paris System for Reporting Urinary Cytology is High Grade Urothelial Carcinoma

HGUC



Approach to Diagnosis in Urinary Tract

Barkan et al JASC 2016;5:177-186



Risk of malignancy – ongoing studies

Category	Risk of Malignancy	Management
Unsatisfactory/Nondiagnostic	10-15%	Repeat cytology, cystoscopy in 3 months if increased clinical suspicion
Negative for HGUC	0-10%	Clinical follow up as needed
Atypical Urothelial Cells (AUC)	8-35%	Clinical follow up as needed. Use of ancillary testing.
SHGUC	50-90%	More aggressive follow up, cystoscopy, biopsy, staging
HGUC	>90%	More aggressive follow up, cystoscopy, biopsy, staging
LGUN	≤10%	Need biopsy to further evaluate grade and stage
Other malignancy	>90%	More aggressive follow up, cystoscopy, biopsy, staging

Poll Question: How is urine cytology reported in your laboratory?

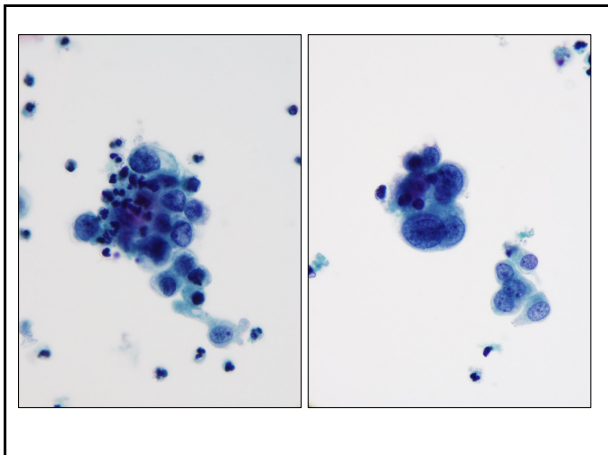
- A. The Paris System
- B. The Paris System with our own modification
- C. Our own system
- D. We don't process urine cytology in our laboratory
- E. I am not sure

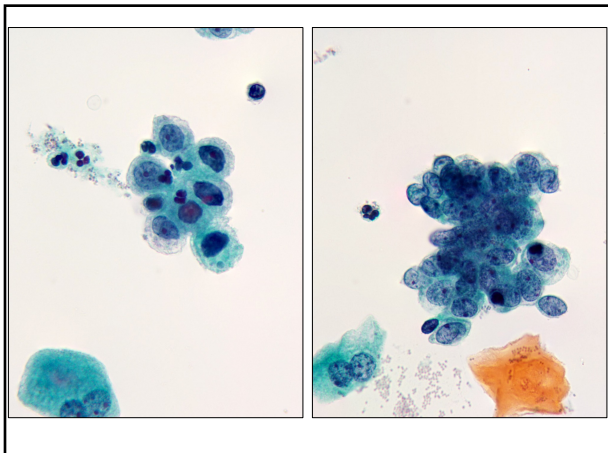


Artwork by Deniz Barkan, 2019

Case 2

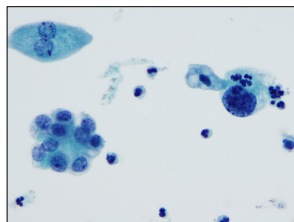
- 72-year-old man presents for evaluation and management of gross hematuria and urinary incontinence
- PMH: Prostatic adenocarcinoma (Gleason 3+3=6, 17 years ago)
- Bladder barbotage specimen is presented



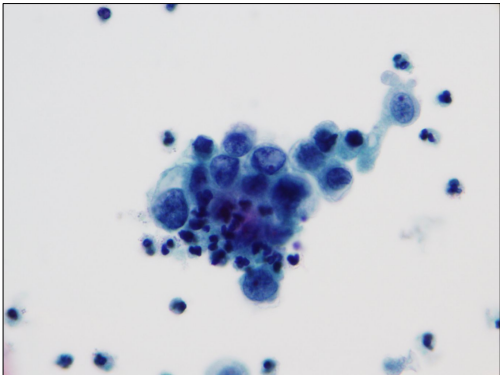


Case 2: What is your diagnosis?

- A. Negative for High Grade Urothelial Carcinoma (NHGUC)
- B. NHGUC. Polyomavirus
- C. Atypical Urothelial cells (AUC)
- D. Suspicious for HGUC
- E. HGUC



Case 2 Diagnosis: AUC

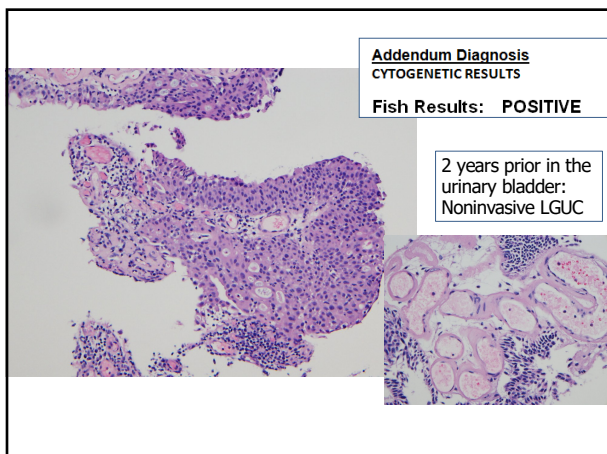


Atypical Urothelial Cells (AUC)

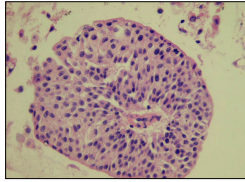
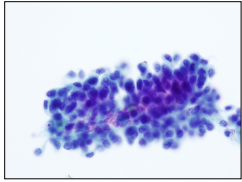
Güliz A. Barkan , Tarik M. Elsheikh , Daniel F. J. Kurtycz , Sachiko Minamiguchi , Hiroshi Ohtani , Eric Platon , Spasenija Savic Prince , Z. Laura Tabatabai , and Christopher J. VandenBussche

Criteria for AUC

- Non-superficial and non-degenerated urothelial cells with a **high N/C ratio > 0.5** (required)
- *and one of the following:*
- **Hyperchromasia** (compared to the umbrella cells or the intermediate squamous cell nucleus)
- **Irregular clumpy chromatin**
- **Irregular nuclear contours**



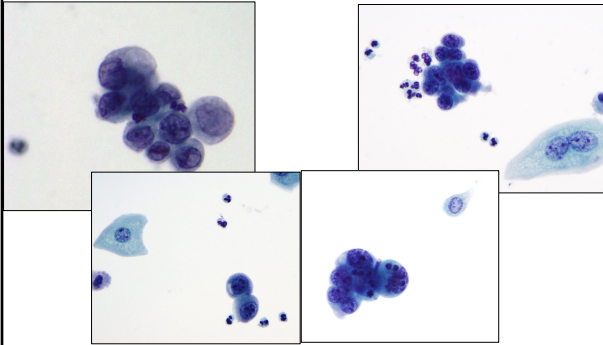
How does LGUN look like in urine?



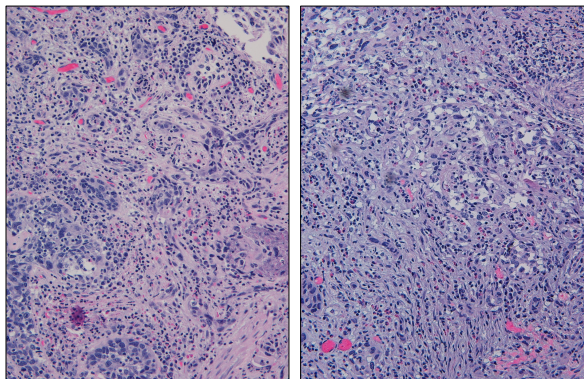
- Cytologically normal nuclei
- Is it truly a carcinoma?
- More common than HGUC, BUT, not life threatening

"A secure diagnosis of a LG UC can be established when tumor fragments with a clearly identified connective tissue stalk or a central capillary vessel are present in the sediment" Koss

Follow up on urine: HGUC



TUR



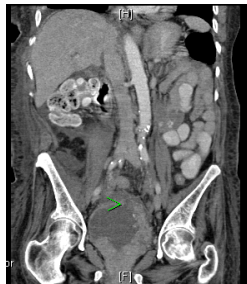
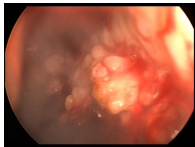


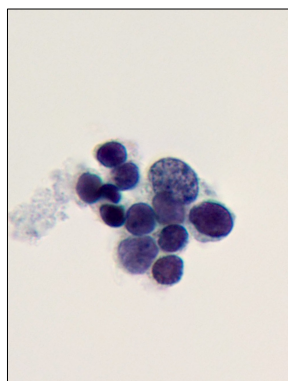
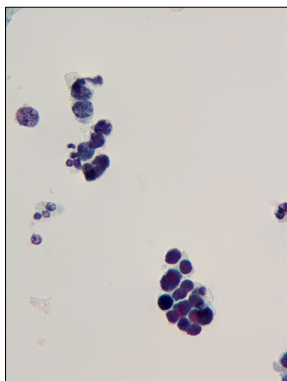
Chicago 3D
by Deniz Barkan, 2019

Case 3

69 –year-old woman
presents to the ED with
gross hematuria and Hgb of
5g/dL

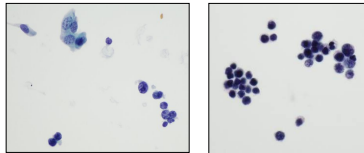
PMH: Hypertension





Case 3: What is your diagnosis?

- A. NHGUC Polyomavirus effect
- B. AUC
- C. HGUC
- D. Other malignancy, favor hematopoietic
- E. Other malignancy, favor non-hematopoietic

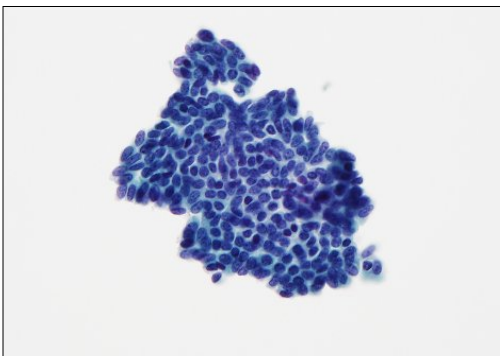


Differential Diagnosis of “Small Cells” in Urine

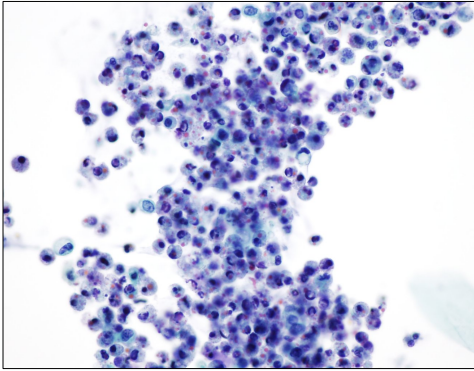
- Normal basal urothelial cells
- Renal tubular cells
- Inflammatory cells (urinary tract infection)
- Hematopoietic malignancy (lymphoma, leukemia, granulocytic sarcoma)
- Small cell carcinoma

Cytomorphologic features and differential diagnosis of neoplasms with small cell features in liquid-based urinary tract cytologic specimens.
Ainechi et al. JASC July 2015

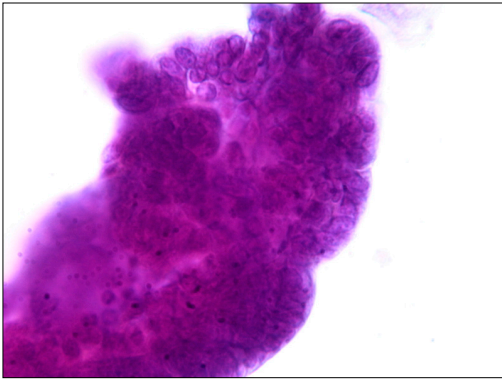
Benign Basal Urothelial Cells



Neobladder urine

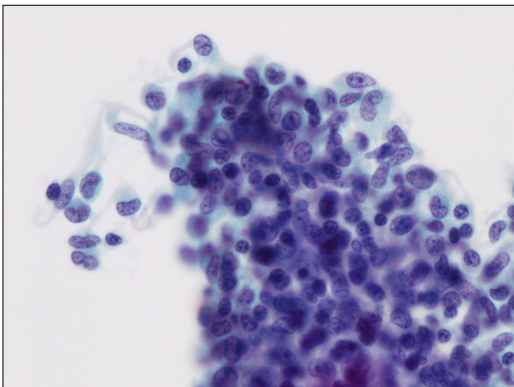


Endometriosis

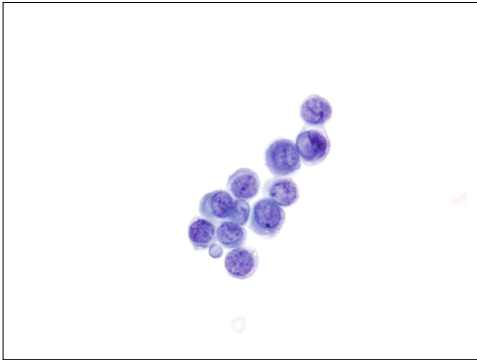


Courtesy of Dr. Praboth Gupta

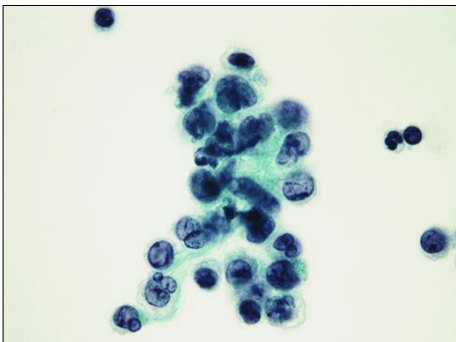
Granuloma



Metastatic lobular carcinoma, of the breast

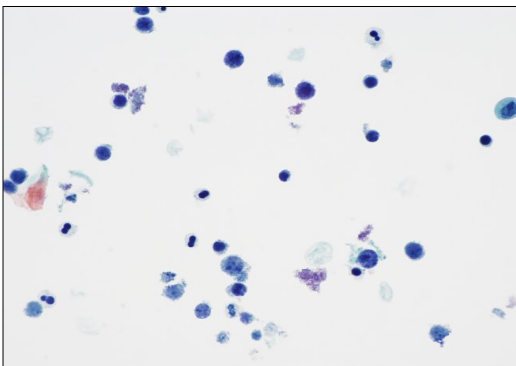


Myeloid leukemia



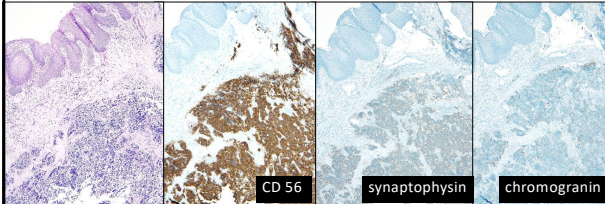
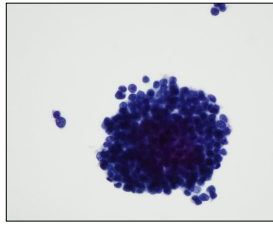
Myeloid leukemia in a urine specimen: a case report and review of the literature.
McCroskey Z, Mehta V, Wojcik EM, Barkan GA. Diagn Cytopathol. 2014 Aug;42(8):700-4


Lymphoma



Case 3 Diagnosis

Small cell carcinoma





Trees of Knowledge
by Deniz Barkan, 2019

Case 4

72-year-old man presenting with hematuria, hesitancy, urgency, and nocturia

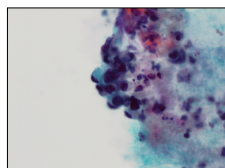
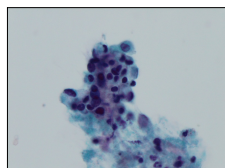
CT: Bilateral hydronephrosis

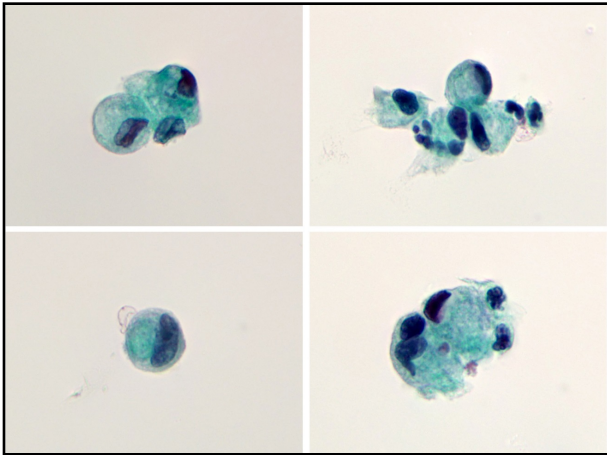
Past medical history:

Partial nephrectomy

Prostatic hypertrophy with obstruction

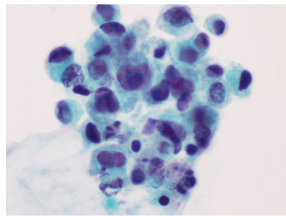
A cystoscopy and bladder barbotage is performed.





Case 4: What is your diagnosis?

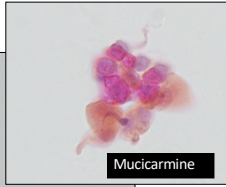
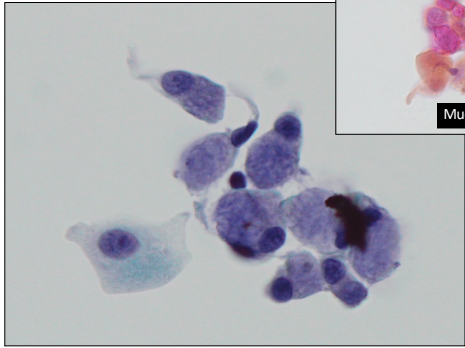
- A. NHGUC
- B. AUC
- C. Atypical cells present
- D. HGUC
- E. Other malignancy



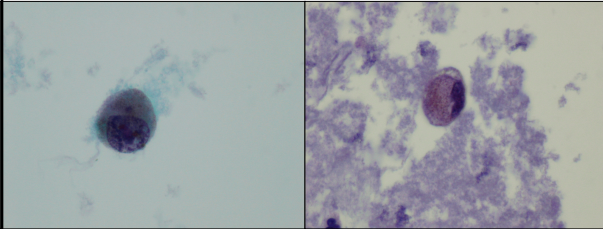
Differential Diagnosis of Glandular Cells in Urine

- Cystitis glandularis
- Reactive urothelial cells
- Ileal conduit urine
- Urothelial carcinoma with glandular differentiation
- Adenocarcinoma, primary bladder (urachal, nonurachal)
- Adenocarcinoma, metastatic
- Signet ring cell carcinoma

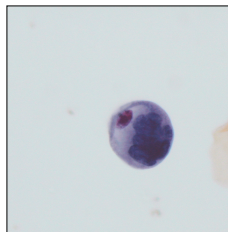
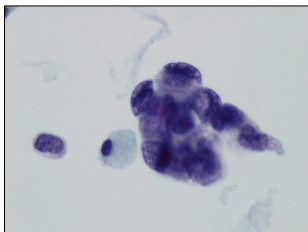
Cystitis Glandularis



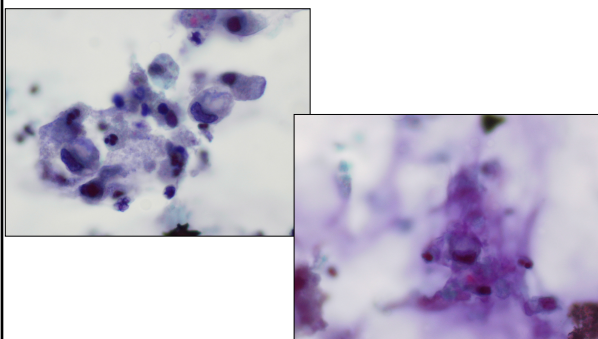
Melanoma



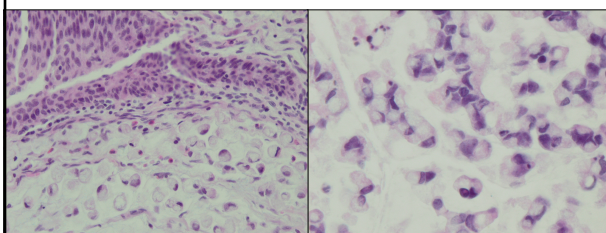
Poorly Differentiated Urothelial Carcinoma



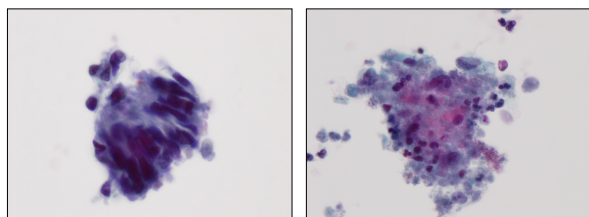
Urachal Carcinoma



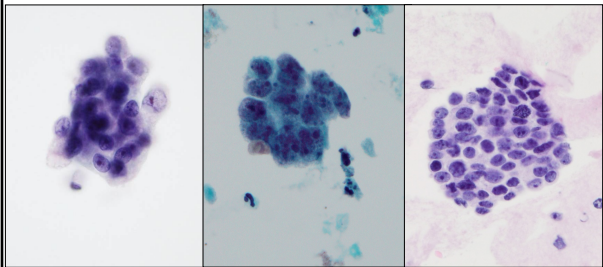
Urachal Carcinoma



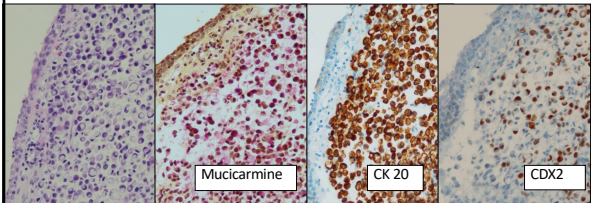
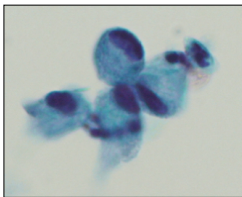
Metastatic colon carcinoma



Prostatic Adenocarcinoma



Signet ring carcinoma



Immunohistochemical Profile : Adenocarcinoma in the Bladder

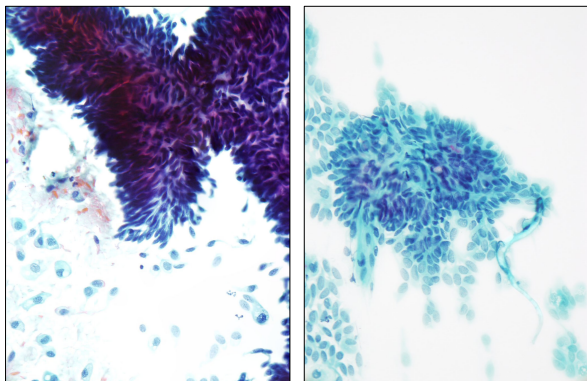
	HMWCK	CK 7	CK 20	PSA	CDX 2	VILLIN	B- catenin
Primary bladder adc, colonic type	+	+/-	+/-	-	+	+/-	-
Primary bladder adc, signet ring cell type	+	+/-	+	-	+/-	+/-	-
Colorectal Adenocarcinoma	-	-	+	-	+	+	+
Gastric Adenocarcinoma	-	+/-	+/-	-	+/-	+/-	+/-
Prostatic Adenocarcinoma	-	-	+/-	+	-	-	-

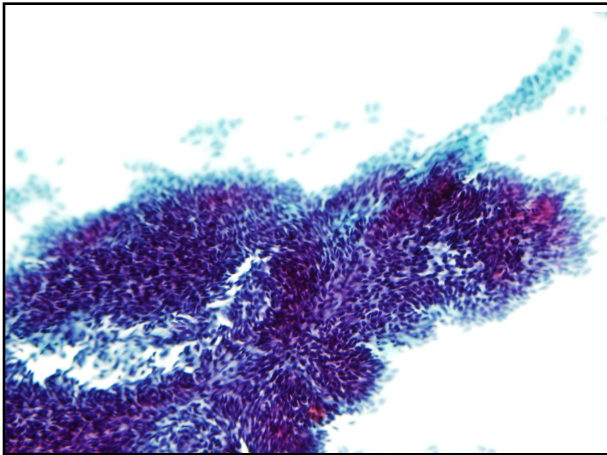


"Istanbul"
by Deniz Barkan, 2019

Case 5

49-year-old woman with a past medical history of diabetes, hypertension, and depression presented with hematuria. CT Urogram revealed a 0.9 cm filling defect in the right renal pelvis and a 2.5 cm upper pole cyst in left kidney. A right renal pelvis washing and brushing was performed.





Case 5: What is your diagnosis?

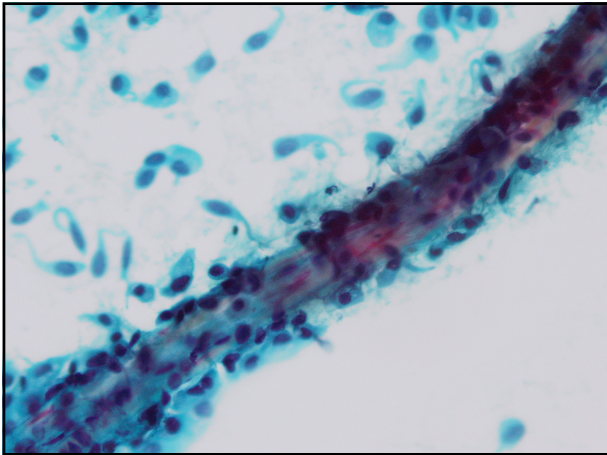
- A. NHGUC
- B. AUC
- C. SHGUC
- D. HGUC
- E. LGUN

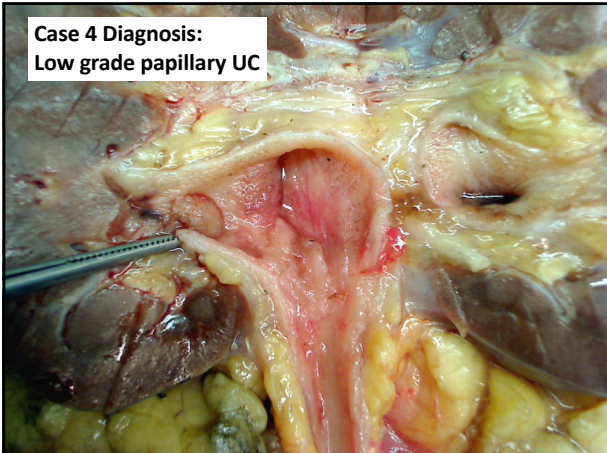
Differential Diagnosis of papillary groups in urine cytology

- Instrumentation Artifact
- Low grade urothelial neoplasms (Papilloma, PUNLMP, LGUC)
- Urolithiasis

Limitation of Urine Cytology:

Koss from *Diagnostic Cytology of the Urinary Tract 1996*: "...this method (cytology) is not suitable for differentiation between effects of instrumentation, lithiasis, and low grade papillary tumors"





About Upper Tract

Criteria doesn't change in the UT although
beware of brushing samples – they can be
cellular!

Cell blocks may be useful in select cases

Knowledge of the endoscopic and radiologic
impression may aid in the diagnosis

For the urologist: Concomitant surgical
pathology increases sensitivity and accuracy

Selective cytology is better than voided urine
in detecting UT UC



"On the road" by Deniz Barkan, 2018



If you like urine cytology, UR in(e) good company!



TPS 2.0 is coming soon.



The "Worldvision Cytopathology Contest" (WCC) is a global outreach initiative of the ASC. WCC offers the opportunity to exchange scientific knowledge and goodwill in a unique cytopathology competition at the ASC's Annual Meeting. For information: Cytopathology.org
